

## ORIGINAL ARTICLE

# Early insertion of inflatable prosthesis for intractable ischemic priapism: our experience and review of the literature

O Sedigh<sup>1</sup>, L Rolle<sup>1</sup>, CLA Negro<sup>1</sup>, C Ceruti<sup>1</sup>, M Timpano<sup>1</sup>, E Galletto<sup>1</sup>, K Soltanzadeh<sup>2</sup>, H Ajamy<sup>2</sup>, J Hosseinee<sup>2</sup>, A Al Ansari<sup>3</sup>, A Shamsodini<sup>3</sup> and D Fontana<sup>1</sup>

<sup>1</sup>SSCVD per l' Andrologia, SCU Urologia, AOU San Giovanni Battista di Torino, Torino, Italy; <sup>2</sup>Infertility and Reproductive Health Research Center, Reconstructive Urology, Shaheed Beheshti Medical Science University, Tehran, Iran and <sup>3</sup>Hamad Medical Corporation and University Hospital, Doha, Qatar

A cohort of 20 patients with delayed priapism who underwent treatment at the Emergency Department of our academic referral centers between January 2002 and April 2010 was studied. Of these, 16 cases suffered from a low-flow priapism. A total of 6 cases were managed non-surgically, 10 required shunt surgery, and of these 5 were treated by early penile prosthesis surgery. Prostheses were easily implanted in all patients with a mean operative time of 94 min. No intraoperative complications and no infection were registered. All patients with an inflatable prosthesis complained a reduction in penile sensibility that lasted 3 months. All patients were satisfied with the results of surgery (International Index of Erectile Function Questionnaire-5, Q5 mean value 4), and all were successfully engaging in satisfactory sexual intercourses. No significant loss of penile length, neither apical erosion nor extrusion was recorded. Early insertion of a penile prosthesis is a simple and safe procedure in patients with ischemic priapism, which failed to respond to conservative management. Early insertion of a prosthesis helps to maintain adequate penile length, resolve priapism and, in the long term, it results in high satisfaction rates.

*International Journal of Impotence Research* advance online publication, 9 June 2011; doi:10.1038/ijir.2011.23

**Keywords:** priapism of penis and clitoris; penile prosthesis; genital lengthening/girth enhancement surgery

## Introduction

Ischemic priapism is a relatively rare sexual-function-threatening andrological emergency, with an incidence of 1.5 per 100 000 person-year.<sup>1</sup> Ischemic priapism can occur at all ages, from newborn to elderly, with an undesirable, rigid and painful erection, which persists in the absence of sexual stimulation, not being relieved by either ejaculation or orgasm.<sup>2,3</sup>

American Urological Association guidelines define priapism as a persistent penile erection, of >4 h in duration, that continues hours beyond, or is

unrelated to, sexual stimulation. Typically, only the corpora cavernosa are affected. Ischemic (veno-occlusive, low flow) priapism is a non-sexual, persistent erection characterized by little or no cavernous blood flow and abnormal cavernous blood gases (hypoxic, hypercarbic and acidotic). The corpora cavernosa are rigid and tender to palpation. Patients typically report pain. A variety of etiological factors may contribute to failure of the detumescence mechanism in this condition. Ischemic priapism is an emergency. Resolution of ischemic priapism is characterized by the penis returning to a flaccid, non-painful state. However, in many cases, persistent penile edema, ecchymosis and partial erections can occur, and it may mimic unresolved priapism. Resolution of priapism can be verified by measurement of cavernous blood gases or blood flow measurement by color duplex ultrasonography.<sup>4</sup>

In the long term, up to 25% of patients with ischemic priapisms induce erectile dysfunction.<sup>3</sup>

Indeed, especially when priapism is not adequately and promptly treated, histopathological

---

Correspondence: Dr O Sedigh, ASO San Giovanni Battista, SSCVD per l'Andrologia, C.so Bramante 88/90, Torino 10126, Italy.

E-mail: dr.sedigh@libero.it

We present our experience in the treatment of refractory ischemic priapism with early inflatable penile prosthesis insertion.

Received 16 February 2011; revised 4 April 2011; accepted 30 April 2011

changes drive the cavernosal tissue toward irreversible fibrosis. This usually happens after 48 h, along with the necrosis of the vasa and corpora cavernosa smooth muscle cells, and with the consequent transformation those smooth muscle cells into fibroblast-like cells.<sup>5,6</sup> It is not clear at which absolute time point such damages become unreversible; moreover, it may also vary according to the etiology of ischemic priapism and the degree of the pre-existing damage of the corpus cavernosum smooth muscles. In this context, it has been demonstrated that after 6 consecutive hours of ischemia, acidosis, glucopenia, hypoxia, hypercapnia and anoxia occur.<sup>7</sup> Both *in vitro* and *in vivo* models have shown that anoxia and glucopenia may function as two independent damaging factors to the corpora cavernosa smooth muscles.<sup>8–11</sup> Finally, there is experimental evidence that irreversible histopathological alterations are caused by the combination of a state of acidosis, glucopenia and hypoxia that last for >4 h.<sup>12</sup>

From the therapeutic standpoint, the initial management is conservative, and involves exercise, aspiration and intracorporal injection of  $\alpha$ -adrenergic agonists, in order to obtain the smooth muscle relaxation, blood outflow and prompt penile detumescence.

A successful outcome of the conservative approach relies on the actual duration of the episode of priapism, being surely more effective (even with the injection of relatively high doses of  $\alpha$ -adrenergic agonists) for episodes lasting <24 h.<sup>13,14</sup> Episodes either lasting >24 h or not responsive to conservative approaches require more aggressive therapeutic strategies, such as shunt surgery.

However, there is no universal consensus about the management of delayed presentations of ischemic priapisms or medical refractory priapism.

In general,  $\alpha$ -adrenergic agonists should be used in all patients, irrespective of the time of presentation, whereas shunt surgery should be offered to the cases of ischemic priapism lasting  $\leq 72$  h, starting with a distal shunt (Winter, Al-Ghorab, Ebbehøj or more recent Brant shunt) and performing a proximal shunt (Quackels, Barry or Grayhack shunt) in cases of distal shunt failure.<sup>15</sup> In this context, the longer the veno-occlusive priapism event, the greater the chance of permanent erectile dysfunction.<sup>15</sup>

There is a group of patients who do not respond to the shunt surgery. In these latter men, and in patients with either a delayed presentation or a severe long lasting condition, erectile dysfunction has to be treated by an elective penile prosthesis surgery in order to contrast the devastating consequences, such as fibrosis and penile shortening.

Likewise, these two groups could benefit by an immediate penile prosthesis implantation, the former group firstly to resolve the dramatic priapic episode, and overall to resume erectile functioning. Thus, early penile prosthesis insertion offers some

advantages, including (a) the resolution of the episode of priapism, (b) the treatment for the inevitable erectile dysfunction and (c) the prevention of penile shortening due to severe fibrosis.<sup>16</sup>

These observations prompted us to present our experience in the treatment of refractory ischemic priapism with early inflatable penile prosthesis insertion.

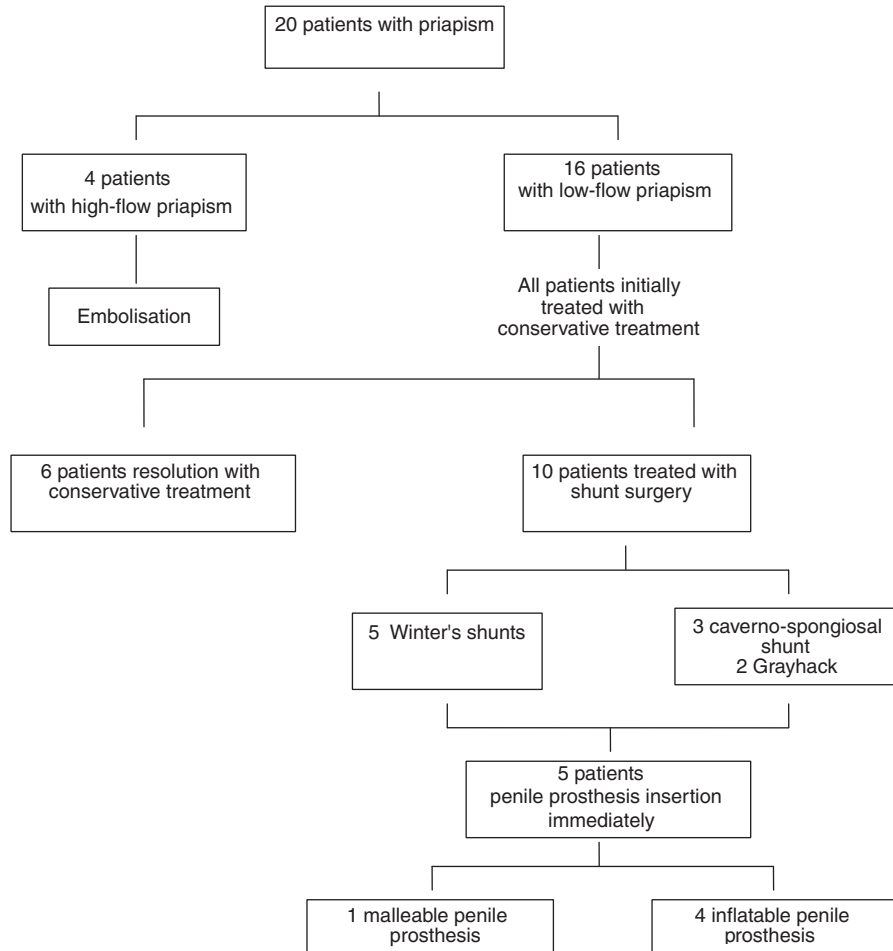
## Materials and methods

The analyses were based on a cohort of 20 patients, studied with delayed priapism treatment (medium rate: 20 h) who underwent treatment for priapism at the Emergency Department of our academic referral center, Molinette University referral center, Torino, Shaid Behesty University of Tehran and Hamad Medical Corporation of Doha, Qatar, between January 2002 and April 2010. Of these, 4 cases were diagnosed with a high-flow priapism, whereas 16 cases suffered from an ischemic, low-flow priapism. Of the former, 6 cases were successfully managed non-surgically, 10 required shunt surgery, and among these 10, 5 were treated by early penile prosthesis surgery (Figure 1). Five patients refused the surgery for co-morbidities and because it was not possible at that moment.

All five patients treated with early insertion of a penile implant had a negative history for sickle cells disease, malignancy, other hematological conditions, such as thrombophilia or other hemoglobinopathies. Likewise, four patients denied the assumption of either any pharmaceutical compound (namely, therapies for erectile dysfunction therapy and systemic/psychiatric disorders) or illicit drugs. In contrast, for one patient, an excessive dose of intracavernosal papaverine was the cause of priapism.

As per protocol, comprehensive blood exams, including fetal hemoglobin assessment, were performed in all patients, with parameters within the normal range of values in all cases. Similarly, cavernosal blood gas evaluation was also performed in all cases; ipoxia and acidosis were found in all subjects, therefore, confirming a low-flow priapism. A conservative approach was thus initially started in all patients.

In this context, cavernosal blood aspiration, injection of phenylephrine (200 mg + 10 ml of NaHCO<sub>3</sub> 20%) and irrigation with antibiotic (gentamycin 80 mg) were performed three times over a period of 8 h, without any successful response, neither partial nor complete detumescence, in all men. Thus, a Winter shunt was initially performed with five holes per apex for each corpus cavernosum without effective results. In one case, a cavernospongiosal shunt was performed without positive functional outcome.



**Figure 1** Algorithm treatment of patient presented with priapism.

Patients who presented with an idiopathic intractable priapism lasting > 36 h (10 patients) had a penile color doppler ultrasound, which confirmed absence of flow in cavernosal arteries and no vascular fistula.

Furthermore, subsequent therapeutic options, with particular regard to the high risk of erectile dysfunction, were then discussed with all patients. Accordingly, we decided to propose an early insertion of an inflatable penile prosthesis in order to resolve the priapic episode, relieve the pain, promote erectile functioning, contemporarily avoiding penile fibrosis and the risks related to a potential delayed insertion of a penile prosthesis into a scarred corporal body. In this context, inflatable prostheses were inserted in four cases (namely, 1 Coloplast Titan OTR (Holtedam 1 Humlebaek, DK, Denmark), 1 AMS 700 LGX (Minnetonka, MN, USA), 2 AMS 700 CX Inhibizone), whereas a malleable prosthesis AMS was chosen for the fifth patient.

Among the five patients refusing the immediate surgery, two of those had Grayhak shunt as requested after counseling without any benefit for erectile function.

*Surgical technique*

For the specific purpose to avoid exceeding risks of infections, only five persons were admitted into the operating room, including two surgeons, the anesthesiologist, a scrub nurse and a further nurse.

Prosthesis was inserted under epidural anesthesia with a broad-spectrum antimicrobial prophylaxis (teicoplanin 400 mg + gentamycin 80 mg). A 16 Ch Foley catheter was placed in all patients. A transverse penoscrotal incision was performed; edema and thickened albuginea was found in all cases. Before the cavernosal dilatation, a biopsy of the corpora cavernosa tissue was also performed. In two cases, frozen sections were performed, and confirmed smooth muscles necrosis, edema of the remaining tissue and blood clots presence; this was not the case in the other three cases, as they had surgery. Dilatation of corpus cavernosum was initially performed with scissor, followed by Haegar dilators, taking care distally to avoid apical perforation and subsequent prosthesis extrusion, in particular in those cases for whom a previous Winter's shunt had been performed. No difficulties were encountered during this maneuver, and an

immediate detumescence was observed. Then corpora were extensively irrigated with gentamycin, and the prosthesis was inserted with 0.5–1 cm oversizing of the cylinder for inflatable implants. Conversely, no oversizing was performed for the malleable prosthesis. To avoid postoperative hematoma formation, a drainage was placed in the scrotum.

Postoperatively, the patient received intravenous antibiotics for 2 further days. In four cases, the indwelling catheter was removed on the first postoperative day; in contrast, the catheter was kept for 1 week and then removed after retrograde cystography in the patient who had previously undergone cavernospongiosal shunt; during the closure of the shunt, there was a small distal uretra perforation that was recognized and sutured; this patient had a suprapubic catheter inserted too to keep the uretra suture as dry as possible. This gentleman was then discharged home after 3 days with oral ciprofloxacin 500 mg b.i.d. for 10 days, and the prosthesis inflated.

## Results

As per surgeon feeling, the prostheses were easily implanted in all patients. Mean operative time was 94 min ( $\pm$  s.d. 31.3 min). In order to close the shunt, 30 min more were used during penile prosthesis implantation in the patient with a cavernospongiosal shunt. In this case, median operative time for only the penile prosthesis implantation was 60 min.

The corporal smooth muscle biopsy was analyzed histologically in the five patients, and all specimens examined revealed necrotic cavernosal smooth muscle.

There were no intraoperative complications and no infection of the penile implants was registered to date. Regarding immediate complications, all patients had a penile hematoma that was resolved within 2 weeks, except in one case in which it disappeared in 1 month (the patients was taking antiaggregant drugs, acetylsalicylic acid 75 mg, for coronary artery disease). All patients with an inflatable prosthesis complained of a reduction in penile sensibility that lasted 3 months (Table 1).

To avoid penile shortening, patients with inflatable prosthesis were instructed to keep the prosthesis inflated for 1 week at home; after 1 week, patients visited at the outpatient clinic where the implant was deactivated in order to prevent an apical extrusion, and they were trained how to use the prosthesis itself. Moreover, patients were encouraged to start at home with at least three cycles of inflation–deflation per day leaving the prosthesis inflated at least for 10 min in each cycle in order to prevent the penile fibrosis and shortening. Moreover, all patients were instructed to not start sexual intercourse before 6 weeks after surgery.

All patients were satisfied with the results of surgery regarding erectile function (International Index of Erectile Function Questionnaire-5, Q5 mean value 4 (s.d.  $\pm$  071)); in this regard, all patients were successfully engaged in satisfactory sexual intercourses after a mean time frame of 2 months. There was no significant loss of penile length in any patient, neither apical erosion nor extrusion because of the cylinder oversizing at the time of implantation, and none of the patients required surgical revision (either for infection, or prosthesis deformity or dysfunction).

Regarding patients refusing the immediate penile implants, two of those had Grayhak shunt in 2 and 3 days after the failure of other shunts, without any benefit of priapism resolution and erectile function restoration postoperative.

They had a close rehabilitation follow-up for erectile function, which included vacuum exercising 20 min two times a day for 6 months, penile stretchers used daily for 3 months, Viagra (Pfizer, New York, NY, USA) 100 daily for 6 months and intracavernosal injection therapy (ICI) 20 mcg daily for 1 month.

All of the patients had penile shortening and severe fibrosis at 6 months follow-up. Mean shortening was 3.5 cm, and all developed an erectile dysfunction not respondent to pharmacological treatment. We implanted a penile prosthesis in one patient after 9 months and in two patients after 12 months. Penile implantation was challenging for severe fibrosis and deformation. The use of Rossello dilators was useful in all cases. Non-infection rate was observed.

**Table 1** Age, time to presentation, shunt, time to penile prosthesis insertion and surgical complications of patients who had a penile prosthesis implanted

Age (years)	Time at presentation at E&A department (h)	Shunt surgery	Time at penile surgery (days)	Surgery complications
34	42	Winter	3	Hematoma and reduction in penile sensibility
56	35	Winter	7	Hematoma and reduction in penile sensibility
64	25	Winter	4	Hematoma and reduction in penile sensibility
33	33	Cavernospongiosal	20	Hematoma and reduction in penile sensibility
73	72	Winter	7	Hematoma

E&A, emergency and accident.

One distal uretra perforation was recognized during cavernospongiosal shunt closure and was treated successfully. A suprapubic catheter and an uretra catheter were placed and kept for 1 month and 1 week, respectively.

## Discussion

The management of ischemic priapism involves successful detumescence and preservation of erectile function. However, such results are not always achieved, and <50% of patients are discharged by hospital, with a penile detumescence and a long-term preservation of erectile function.

Although it is not actually known what is the crucial time for irreversible damage to smooth muscle cells, hypoxia, glucopenia and acidosis are independent negative prognostic factors for the recovery of erectile function; these events occur within 6 h from the beginning of the priapic event. The lasting time at medical presentation seems to be an important predictive factor of the sexual outcome, being 24 h of unsolved priapism a crucial time; >90% of patients with a priapism lasting >24 h complain of subsequent erectile function impairment; conversely, patients with priapism reversal within 24 h from the onset have a 50% chance of recovery of a normal erectile function.<sup>13,14</sup>

Whenever priapism is left untreated, it may tend to subside with time, but with the replacement of the vascular smooth muscles with fibrotic tissue, it may result in a shortened and fibrotic penile shaft. This eventually leads to a more difficult penile prosthesis implantation, which has to be discussed with the patient in order to provide the most suitable management.

The option of an early penile prosthesis insertion may offer a number of potential advantages. It allows the recovery of sexual function, normally lost in long-lasting priapism; it may prevent penile shortening, which ultimately occurs as a consequence of fibrotic changes in the corpora cavernosa; moreover, it is easier to implant a penile prosthesis in the acute setting, with fewer complications as compared with the delayed implantation due to the degree of the corpora fibrosis.

In order to avoid an overtreatment, the cornerstone of this approach is the correct timing, which is irreversible. As previously debated, the actual time frame is not known over which damages became irreversible and erectile dysfunction eventually occurs; some authors consider that 24–48 h should be probably considered the corner time, as a priapic penile shaft does not positively resolve with a medical approach, an immediate penile insertion should be considered and discussed with patient. In our experience, if pain is well controlled with medical treatment, the definite treatment by insertion of penile prosthesis could be delayed by some

days, without meeting disruptive and strong corpora cavernosa fibrosis. In this paper, we reported a non-challenging penile prosthesis insertion even after 1 week of priapism; more studies are needed to better define the cutoff time, over which the fibrotic process makes surgery challenging, but it is absolutely better to delay for 1 week also for better counseling and understanding of the patients and partners. The correct time for implantation in our opinion is before 20 days. The three patients operated after 9 and 12 months showed an average penile shortening of 3.5 cm, severe fibrosis causing difficult implantation and the need to use shorter cylinders, leading to a higher risk of malfunction and revision of surgery.

Another important key is the surgical management preceding the penile insertion. It is widely accepted that a priapism that does not respond to medical therapy should undergo shunt surgery. Several approaches have been suggested, ranging from the easy transglandular spongiorporal shunt to the more difficult saphenocorporal shunt. Although effective, shunt surgery may expose the patients to an increased risk of complications in those without a successful outcome and who, ultimately, may represent suitable candidates for an immediate penile implantation.

In particular, apical shunts expose patients to an increased risk of apical perforation during corporal dilatation, and so prosthesis extrusion. Al-Gorhab and the techniques of Brant *et al.*<sup>17</sup> are actually the two easiest to perform and more efficacious shunts, but undoubtedly may expose patients to a very high risk of apical perforation during penile prosthesis implantation either in an acute setting or in an elective setting. Recently Salem and El Aasser<sup>18</sup> reported a successful early penile prosthesis implantation in distal refractory priapism of the shunt (Al Ghorab and Winter). In their series, a non-absorbable sling suture was taken through the cylinder and the edges of the opened tunicae albuginea to fix the cylinder to the corporotomy edges. This approach, even if effective, simple and safe, is limited to the implantation of malleable prosthesis. Therefore, we personally feel that they should be performed with caution, especially in those men presenting with long lasting priapism for whom resolution of the priapic event and restoration of erectile function might be really difficult to achieve with a conservative approach. We report two apex erosions after 6 months of failed Al-Gorab shunts, during penile implantation for erectile dysfunction (ED). Unfortunately, there is no consensus on the right shunt to perform in relation to the priapic episode lasting time. Brant *et al.*<sup>17</sup> suggested a T-shaped apical shunt, which was able to treat priapism along with a contemporary preservation of an intact erectile functioning in 11 out of their 13 consecutive cases (priapic lasting time from 17 h to 14 days).

Lian *et al.*<sup>19</sup> reported disappointing results with Al-Ghorab shunt plus intracavernous tunneling for prolonged ischemic priapism in terms of erectile function. In their series, erectile function after shunt plus tunneling significantly decreased compared with that before the ischemic priapism, as the results of quality of life score, which were also significantly decreased than that before ischemic priapism.<sup>19</sup> More data are needed to confirm these findings.

A matter of discussion in this particular surgical setting is the choice of the most appropriate penile prosthesis in the acute setting. In Ralph's papers,<sup>20,21</sup> although he used inflatable prostheses, the author clearly preferred to implant malleable prosthesis in an acute setting, as interim prosthesis, because it may offer some advantages: the surgical procedure is shorter, with a lower risk of infection, the malleable prosthesis eventually being able to prevent fibrotic shortening. We believe that all these considerations are certainly correct; however, placing an interim prosthesis means that patients should undergo one more surgical intervention, with higher psychological and economic costs. In contrast, inflatable prosthesis offers the advantage of an immediate and definitive resolution of the problem; prevention of fibrotic shortening could be achieved with the use of AMS LGX or cylinder oversizing/coloplast OTR; reduction of infections rate could be achieved with limited numbers of staff admitted to the operating room, use of an inhibizone prosthesis and administration of antibiotics for a relatively long period. So we believe that the choice of the prosthesis is up to the patient.

In order to prevent penile shortening, oversizing is another important keypoint when performing an immediate inflatable penile prosthesis insertion. The aim is to avoid penile shortening, contrast the retraction due to fibrosis. This could be achieved either by a cylinder oversizing of 0.5–1 cm or with implantation of AMS 700 LGX, which provide a lengthening of roughly 18% of the cylinder during its inflation. As it has been only recently launched in the market, we only implanted a AMS 700 LGX in one patient with satisfactory results and without complications or apical perforation/extrusion. Even if our experience is limited to one case, the absence of increase in complication or malfunctioning rate drives us to conclude that AMS 700 LGX could be very useful in this particular surgical setting.

### Conclusions

In some patients who do not respond to conservative management, the smooth muscle is likely to be necrotic, and therefore attempts to re-oxygenate them through shunt surgery would be futile.

Magnetic resonance imaging is very useful for correct diagnosis and to avoid apical shunts, which increases complications in future surgery.

Early insertion of a penile prosthesis is a simple and safe procedure in patients with ischemic priapism that fail to respond to conservative management. Early insertion of prosthesis helps to maintain adequate penile length, resolve the episode of priapism and contrasts all of the devastating complications of corpora retraction and, in the long term, results in high satisfaction rates.

### Conflict of interest

The authors declare no conflict of interest.

### References

- Eland IA, van der Lei J, Stricker BH, Sturkenboom MJ. Incidence of priapism in the general population. *Urology* 2001; **57**: 970–972.
- Pryor J, Akkus E, Alter G, Jordan G, Leuret T, Levine L *et al.* Priapism. *J Sex Med* 2004; **1**: 116–120.
- Nehra A. Priapism. Pathophysiology and non-surgical management. In: Porst H, Buvat J (eds). *Standard Practice in Sexual Medicine*. Blackwell Publishing: Boston, MA, 2006, pp 174–179.
- Montague DK, Jarow J, Broderick GA, Dmochowski RR, Heaton JP, Lue TF *et al.* Members of the Erectile Dysfunction Guideline Update Panel; Americal Urological Association. American Urological Association guideline on the management of priapism. *J Urol* 2003; **170**(4 Part 1): 1318–1324.
- Spycher MA, Hauri D. The ultrastructure of the erectile tissue in priapism. *J Urol* 1986; **135**: 142–147.
- Ul-Hasan M, El-Sakka AI, Lee C, Yen TS, Dahiya R, Lue TF. Expression of TGF-beta-1 mRNA and ultrastructural alterations in pharmacologically induced prolonged penile erection in a canine model. *J Urol* 1998; **160**(6 part1): 2263–2266.
- Broderick GA, Harkaway R. Pharmacologic erection: time-dependent changes in the corporal environment. *Int J Impot Res* 1994; **6**: 9–16.
- Broderick GA, Gordon D, Hypolite J, Levine RM. Anoxia and corporal smooth muscles dysfunction. *J Urol* 1994; **151**: 259–262.
- Kim NN, Kim JJ, Hypolite J, García-Díaz JF, Broderick GA, Tornheim K *et al.* Altered contractility of rabbit penile corpus cavernosum smooth muscle by hypoxia. *J Urol* 1996; **155**: 772–778.
- Saenz de Tejada I, Kim NN, Daley JT, Royai R, Hypolite J, Broderick GA *et al.* Acidosis impairs rabbit trabecular smooth muscle contractility. *J Urol* 1997; **157**: 722–726.
- Moon DG, Lee DS, Kim JJ. Altered contractile response of penis under hypoxia with metabolic acidosis. *Int J Impot Res* 1999; **11**: 265–271.
- Burnett. Priapism. In: *Campbell's Urology*, 9th edn. (Walsh PC, Retik AB, Vaughan ED, Wein AJ (eds)). Amsterdam: Elsevier.
- Pohl J, Pott B, Kleinhans G. Priapism. A three-phase concept of management according to aetiology and prognosis. *BJU Int* 1986; **58**: 113–118.
- Broderick GA, Harkway R. Pharmacological erection: time-dependent changes in the corporal environment. *Int J Imp Res* 1994; **6**: 9–16.
- Munarriz R, Wenn CC, McAuley I, Goldstein I, Traish A, Kim N. Management of ischemic priapism with high-dose intracavernosal phenylephrine: from bench to bedside. *J Sex Med* 2006; **3**: 918–922.

- 16 Muneer A, Minhas S, Freeman A, Kumar P, Ralph DJ. Investigating the effects of high dose phenylephrine in the management of prolonged ischemic priapism. *J Sex Med* 2008; **5**: 2152–2159.
- 17 Brant WO, Garcia MM, Bella AJ, Chi T, Lue TF. T-shaped shunt and intracavernous tunneling for prolonged ischemic priapism. *J Urol* 2009; **181**: 1699–1705.
- 18 Salem EA, El Aasser O. Management of ischemic priapism by penile prosthesis insertion: prevention of distal erosion. *J Urol* 2010; **183**: 2300–2303.
- 19 Lian W, Lv J, Cui W, Jin Z, Liu T, Li W *et al*. Al-Ghorab shunt plus intracavernous tunneling for prolonged ischemic priapism. *J Androl* 2010; **31**: 466–471.
- 20 Rees RW, Kalesi J, Minhas S, Peters J, Kell P, Ralph DJ. The management of low-flow priapism with the immediate insertion of a penile prosthesis. *BJU Int* 2002; **90**: 893–897.
- 21 Ralph DJ, Garaffa G, Muneer A, Freeman A, Rees R, Christopher AN *et al*. The immediate insertion of a penile prosthesis for acute ischaemic priapism. *Eur Urol* 2009; **56**: 1033–1038.